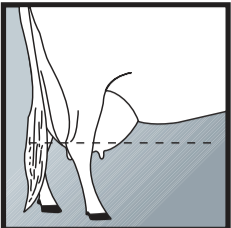
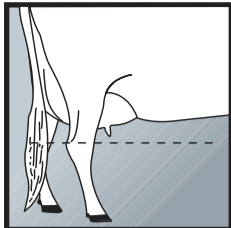


mammary system

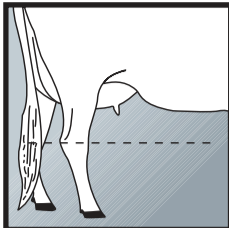
UDDER DEPTH from hock to floor of udder



1 DEEP




5 INTERMEDIATE




9 SHALLOW


UDDER TEXTURE softness and expandability



1 FLESHY

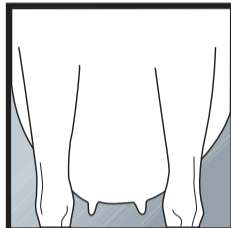


5 INTERMEDIATE

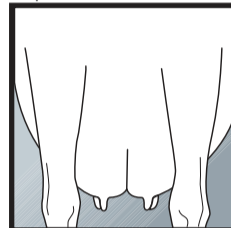


9 SOFT

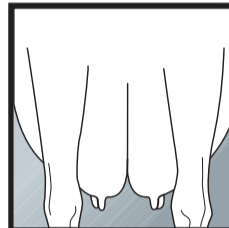
MEDIAN SUSPENSORY depth of cleft (fore/rear)



1 WEAK

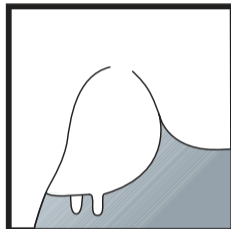


5 INTERMEDIATE




9 STRONG


FORE ATTACHMENT attachment to abdominal wall



1 WEAK

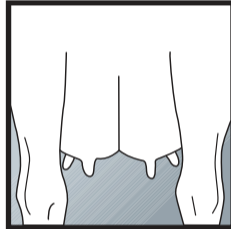


5 INTERMEDIATE

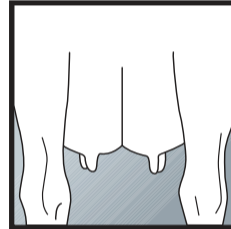


9 STRONG

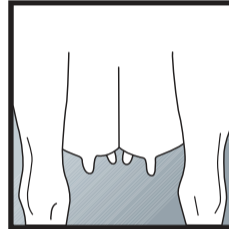
FRONT TEAT PLACEMENT teat placement from centre of quarter



1 WIDE

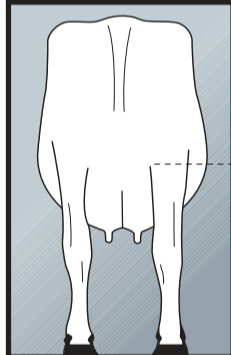


5 CENTRE

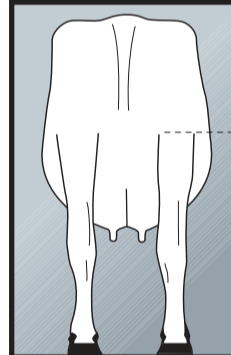


9 CLOSE

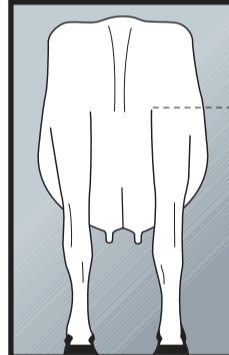
REAR ATTACHMENT HEIGHT milk secreting tissue to base of vulva



1 LOW

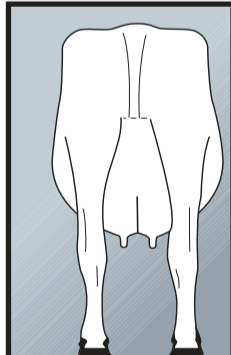


5 INTERMEDIATE

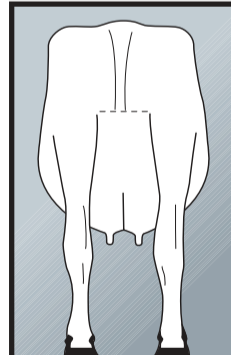


9 HIGH

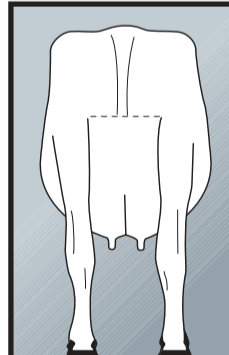
REAR ATTACHMENT WIDTH width at milk secreting tissue



1 NARROW

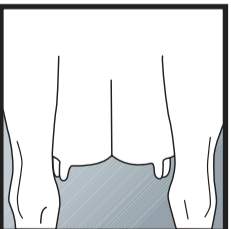


5 INTERMEDIATE

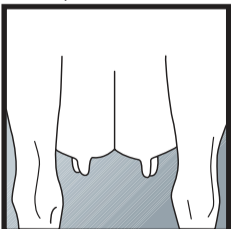


9 WIDE

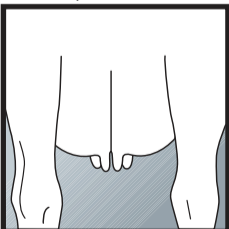
REAR TEAT PLACEMENT teat placement from centre of quarter



1 WIDE

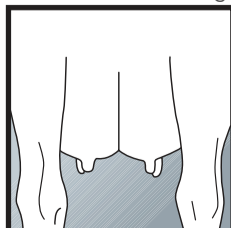


5 CENTRE

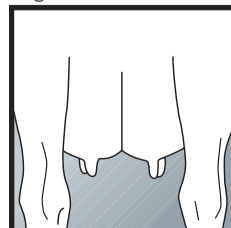


9 CLOSE

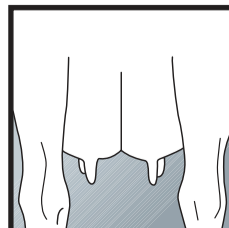
TEAT LENGTH average length of rear teats



1 SHORT



5 INTERMEDIATE



9 LONG